



Update on the 'index technique' in worn dentition: a no-prep restorative approach with a digital workflow

Riccardo Ammannato, DDS

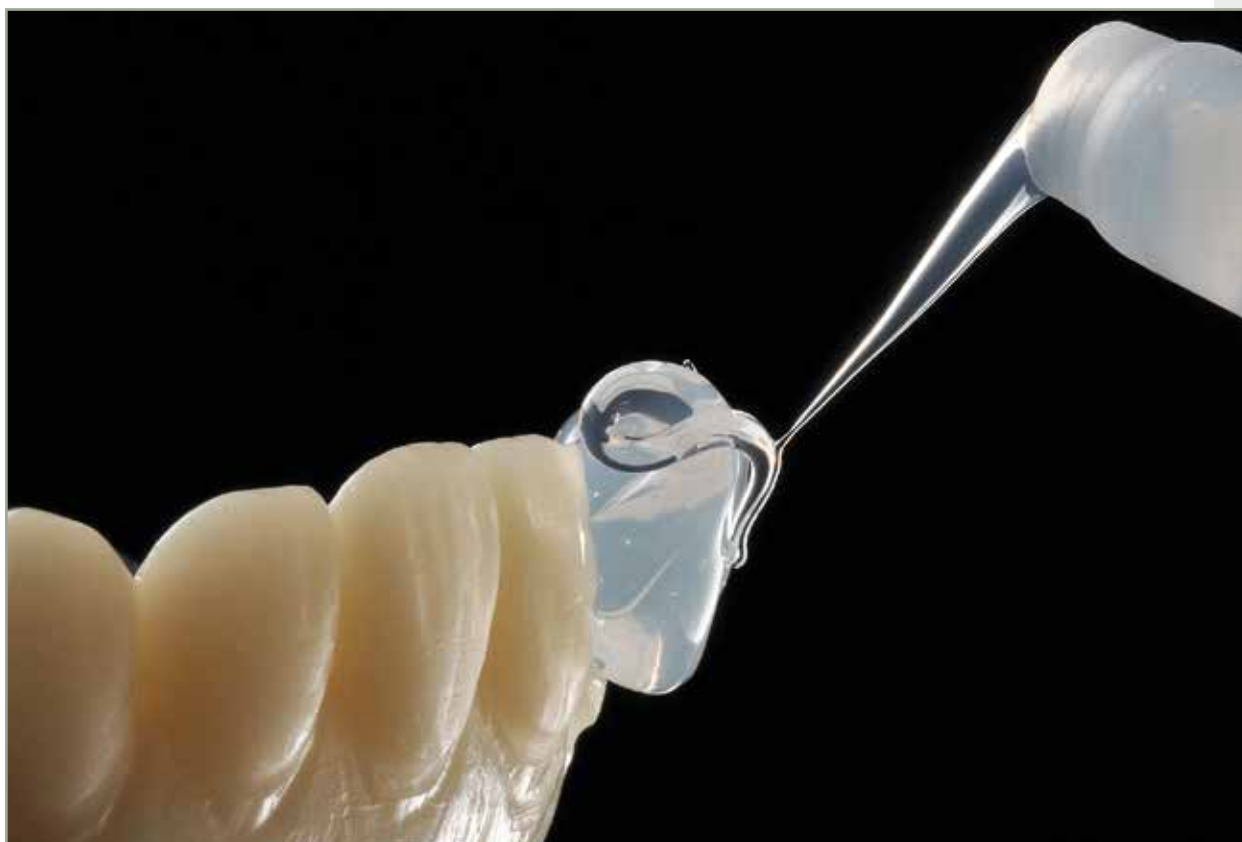Private Practice, Genova, Italy

Daniele Rondoni, CDT

Private Practice, Savona, Italy

Federico Ferraris, DDS

Private Practice, Alessandria, Italy



Correspondence to: Dr Riccardo Ammannato

Salita S Caterina 2/6, Genoa, 16123, Italy; Tel: +39 010 3742354, Mobile: +39 347 47734\19; Email: rammannato@libero.it;
www.studioammannato.com

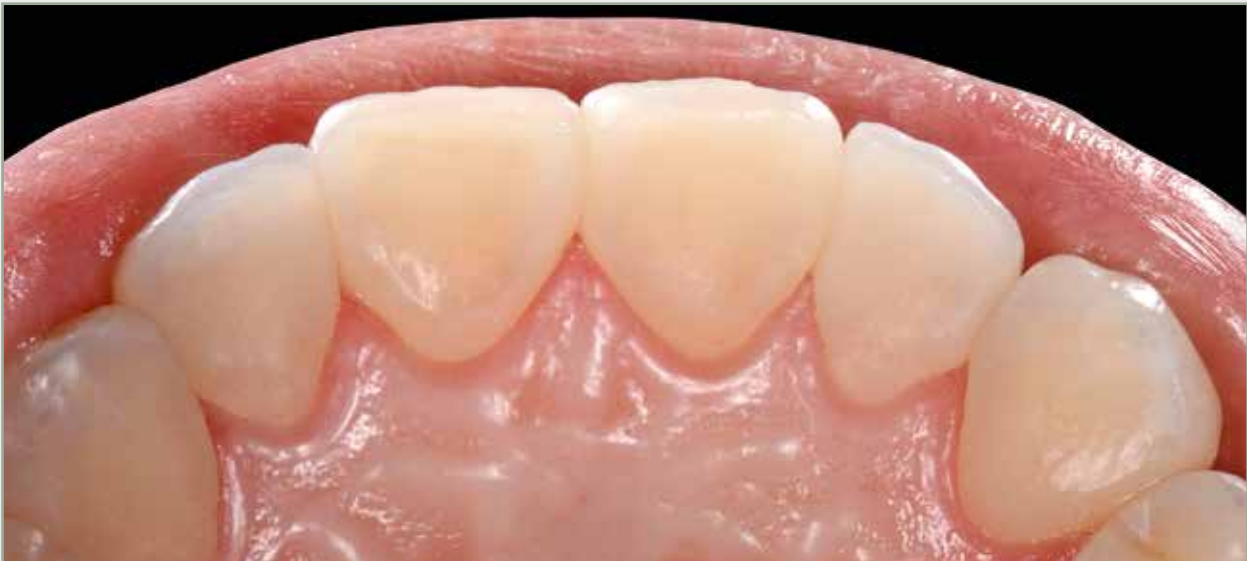

Abstract

Following the guidelines of the 'index technique' that were published in this journal in 2015, this article presents the 'digital index technique,' an updated no-prep restorative approach to the management of worn dentition. Patients with minimal, moderate, and severe hard tissue wear can be treated based on the application of minimally invasive or noninvasive adhesive composite restorations on posterior and anterior worn dentition. The technique allows for a purely additive treatment without sacrificing healthy hard tooth tissue. It follows the principles of biodentistry (maximum conservation of healthy tissue), and the reinforcing of residual dental structure. Depending on the severity of the enamel and dentin wear, the number of caries, and the size of the existing restorations, different treatment options can be applied

to each tooth: direct and indirect partial restorations or full crowns. It is essential to diagnose and treat tooth surface loss in order to properly restore biomechanics, function, and esthetics by means of adhesive restorations. This article proposes that the update of the index technique through the digital workflow is a fast and conservative approach for the planning and management of a full-mouth adhesive restoration in all cases of light, moderate, and severe worn dentition. The technique is based on a 'copy-and-paste' guided approach, stamping composite resin directly onto the tooth surface by means of a transparent index created from a full-mouth digital restorative wax-up, following an initially planned increase in occlusal vertical dimension (OVD) through an esthetic and functional analysis.

(Int J Esthet Dent 2018; 13:2–24)





Introduction

The following factors should be considered during the initial diagnosis: loss of enamel/dentin, loss of periodontal support, periapical lesions or insufficient root canal treatments, insufficient existing restorations, and any recurrent or new decay. All of the urgent/emergency treatment should be carried out prior to the planning of the index technique.

A precise diagnosis for the cause of the dental wear should be established in order to understand whether the origin is physical (bruxism or attrition) or chemical (erosion due to endogenous or exogenous substances).¹ In recent years, the increase of tooth wear has been a major concern among dental professionals.¹ The multifactorial causes that trigger tooth erosion include behavioral changes and an unbalanced diet, and various medical conditions such as acid regurgitation and medications that influence saliva composition and flow rate.² Furthermore, bruxism (awake and sleep) is a widespread functional disorder that also induces severe tissue attrition. All these factors must be taken into consideration when managing worn dentition.

Before a restorative procedure takes place, patients should begin a strict oral hygiene and maintenance protocol, including the use of fluoride and chlorhexidine to reduce the risk of caries. Dietary habits need to be examined, and acidic food and drink intake reduced.³

A full esthetic evaluation is carried out, with photographs and a video reproducing the face and smile in a dynamic situation. A digital smile project is also performed to better evaluate the esthetics and communicate with the patient.

In cases where increasing the occlusal vertical dimension (OVD) is carried out with the index technique, BruxChecker (Scheu Dental) is used to investigate further friction and/or the patient's dynamic movements while sleeping.⁴ This device is also used for the same reasons after the case has been finalized. This information is essential for the clinician and dental technician to properly evaluate the patient before being able to plan an esthetically and functionally driven digital restorative wax-up that evaluates the occlusal plane, anterior guidance, canine guidance, and occlusal stability on the posterior sextants.^{5,6}

The index technique is developed through a 'reorganizational' approach, where the OVD requires altering to create the correct interocclusal space for the restorations to be carried out. In order to record the centric relation (CR), the patient is 'deprogrammed' by means of a leaf gauge,^{7,8} aiding the condyles in a superior/anterior position through a self-induced technique.

Following this, wax records are taken with a heated, folded sheet or a silicone-based material on the posterior quadrants, with the leaf gauge in between sextants 2 and 5, in order to register a new OVD in CR.

The dental technician receives from the clinician a file of the digital impression of the two dental arches, and another file with the two arches while biting on the wax record of the new OVD in CR.

The final restorative steps of this technique can start from the anterior or posterior sextants.

Early diagnosis of tooth wear is essential in order for the clinician to restore the teeth with an adhesive technique by



means of direct and indirect partial restorations to recreate tooth anatomy, function, and esthetics as well as to prevent further tooth loss. The approach presented in this article (following that published in this journal in 2015),⁹ avoids or at least postpones a more complex and invasive prosthetic rehabilitation, like full or partial indirect restorations, ultimately having a positive biomechanical impact on long-term maintenance.¹⁰⁻¹³ Many authors have suggested, and proven through follow-ups, that it is reliable to use adhesive systems and composite resin (direct and indirect) in all cases of worn dentition.¹⁴⁻²⁷ The behavior of composite resin with the opposing natural enamel should also be considered, since its wear is four times faster, given also that ceramic wears three times slower when opposing natural dentition.²⁸

Lithium disilicate has become a valid alternative to composite resin restorations in recent years due to its mechanical properties.

The digital workflow in the clinic, but especially in the laboratory, has the advantage of speeding up all the restorative procedures.

Treatment guidelines

The evaluation and selection of suitable restorations to be placed in each posterior sextant has to be done taking into consideration the amount of healthy residual hard tissue, the thicknesses of the present enamel and dentin, the endodontic and periodontal implications, and the amount of OVD that needs to be increased. However, it is important to note that in some cases it is not necessary to

treat all four posterior sextants, ie, it is enough to treat only the two mandibular posterior sextants due to moderate wear with an inverted Curve of Spee.²⁹

Whenever possible, according to the indications and when the residual tooth tissue allows, a direct restoration using composite resin to restore worn dental surfaces⁹ will always be performed using the protocol described in this article. Various degrees of wear have been classified, each requiring different types of restorations. In some cases, only occlusal, linguopalatal, or buccal restorations will need to be placed. Where large and deep cavities are present on posterior teeth, performing the index technique following adhesion could be very stressful for residual sound tissue due to an unfavorable 'C factor' situation.³⁰ Hence, to minimize shrinkage, the first part of the layering is done according to a conventional approach (free-hand layering), while the last occlusal part is performed with the index technique.⁹ However, with evolving technology there are now composites on the market that allow for thicker layers, lower volume shrinkage, lower weight contraction stress, and a good chromatic integration (Tetric EvoCeram Bulk Fill, Ivoclar Vivadent).

In situations where the 'C factor' component is more favorable (small cavities, and moderately worn posterior and anterior dentition), the standard index technique⁹ protocol is routinely applied following the initial adhesive steps.

Generally, sextant 1 can be treated during the first appointment, sextant 3 during the second, sextant 4 during the third, and sextant 6 during the fourth appointment. It is also possible to treat



two antagonist sextants during the same appointment, or all posterior sextants at the same time, depending on the time available.

Where there is an indication for indirect restorations varying from ceramic or composite onlays to full-coverage ceramic crowns, the conventional prosthetic techniques are carried out by means of standard impressions or computer-aided design/computer-aided manufacturing (CAD/CAM) technology.

There is no 'correct' clinical sequence when applying indirect restorations, since all the direct restorations will already have been carried out and a stable occlusion achieved. The canines will always be the guidelines for the occlusion, with bilateral contacts holding shim stock and articulating paper.

A clinical case

The main complaint of this 23-year-old female patient was sensitivity due to erosion in the posterior teeth, and a slight tension in the cheek muscles on awakening in the morning. Due to these symptoms, magnetic resonance imaging (MRI) was performed to evaluate the temporomandibular joints (TMJs). The patient also wanted to change the shape and size of her anterior teeth without them being touched. The slight muscle tension was managed by bite therapy prior to the start of treatment, as it is only possible to proceed with treatment once this tension has been resolved. The patient was advised to undergo orthodontic treatment to achieve a correct overbite and overjet prior to considering any restorative procedure; however, she declined this

advice due to a previous treatment that had been completed 2 years previously. Her posterior teeth were sensitive to temperature, and her anterior teeth were short, especially in sextant 5. Her four wisdom teeth were extracted. A complete esthetic and functional analysis was carried out in order to perform a diagnosis, prognosis, and treatment plan.

The laboratory digital workflow

Once the digital impression of the two arches and the file with the bite registration interposition in CR at the new OVD (STL files) (Figs 1 to 4) were received from the clinician, they were checked to ensure that all the information and details had been detected in order to properly finalize the digital wax-up.

The digital models were then mounted on a digital semi-adjustable articulator (Artex CR, Amann Girrbach) (Fig 5) in CR at the new OVD. A digital facebow was also included for an arbitrary esthetic plan. The digital order form was then filled in and the digital project could begin. Each tooth to be restored was selected on the order form by clicking on 'temporary prepared model' in order to create the shape without applying any finishing lines and having no limits from the software regarding the thickness, offset, and margin lines. The teeth selection is also very important for the correct insertion axis. This is checked automatically by the software, which eventually cuts out important parts of the model.

The most suitable library is then selected based on the patient's age and tooth shape as well as the outcome of the digital smile virtual model performed in the diagnostic phase. In this case, a

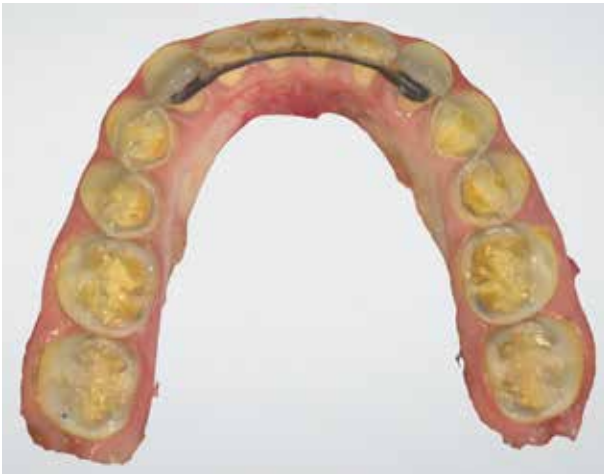

Fig 1 Initial impression (STL file) of the mandibular arch.

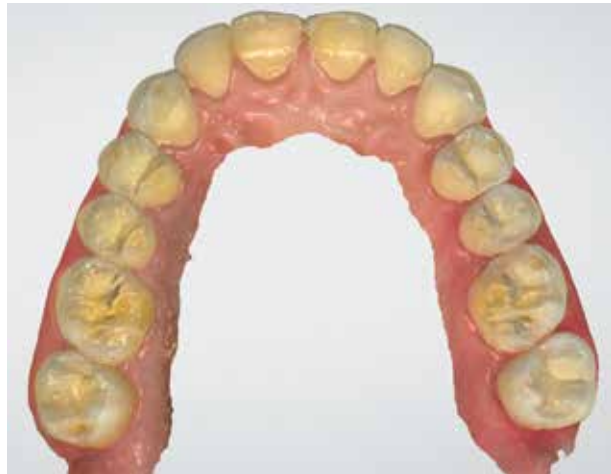

Fig 2 Initial impression (STL file) of the maxillary arch.

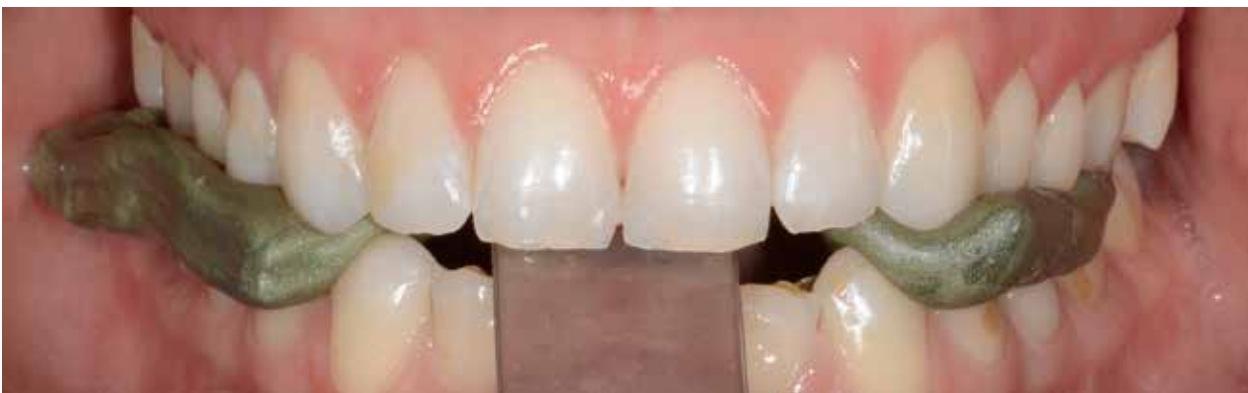

Fig 3 The patient is deprogrammed by means of a leaf gauge through a self-induced technique in order to record the CR.

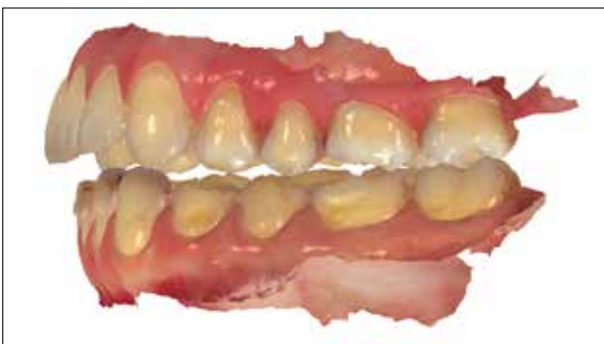

Fig 4 Initial impression (STL file) with the bite registration interposition and the leaf gauge (which the software is able to remove) in CR at the new OVD, based on the functional and esthetic analysis.

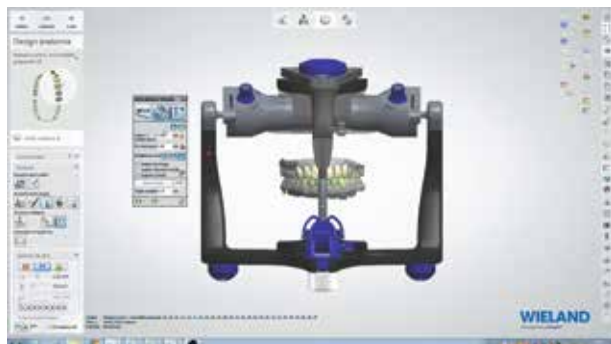

Fig 5 Static and dynamic occlusal contact points are checked.



triangular shape library and an adult age model were selected.

The elements were positioned one by one following an esthetic guide and a correct occlusal plane in order to achieve a good functional and esthetic project (teeth 17 and 27 were not included in the project because they were intact). Once modeling had been carried out, the static and dynamic occlusal contact points were checked by means of a virtual semi-adjustable articulator (3 Shape), with settings that can be partially customized (Figs 5 and 6). The final goal for the project was to achieve a stable posterior occlusion and an efficient anterior guidance.

By clicking on the two-dimensional (2D) option, it was possible to section each element and model, checking thicknesses, contact areas, and distances from antagonist of the entire digital wax-up. This process can also help the clinician and technician to choose the correct restorative material by checking the thicknesses of all the occlusal surfaces (Fig 7).

A virtual sectioning for micromodel milling was performed and imported into the CAM, where in this case a monochromatic polymethylmethacrylate (PMMA) was selected. Then, the milling parameters were set and the milling carried out, leading to six (three each for the maxilla and mandible) PMMA-milled micromodels (Fig 8). On each micromodel, a 72-shore transparent silicone index (Memosil 2, Kulzer or Temp Silk, Micerium) was built by means of a dispenser syringe (Fig 9). For better finishing, the index surface can be manually smoothed with a drop of liquid soap on a finger before chemical curing, if the index is built freehand.

Alternatively, a transparent or individual impression tray can be used. In this way, the material viscosity can be properly managed, as can polymerization, thicknesses, and the uniformity needed to guarantee elastic memory.

Two bar pressure polymerization was then carried out by means of a hydrothermal polymerization process to guarantee compactness and the total absence of microbubbles (Fig 9).

Anterior and posterior temporary mock-up

When raising the OVD in such cases, it is also possible to try the mock-up on the four posterior sextants for a certain period, together with the anterior mock-up. This is done to test esthetics (to see whether the amount of OVD raised is suitable for that specific case) as well as to check function and static and dynamic occlusion outside of the clinic in 'normal' life. These are essential steps in the therapy, since the patient, clinician, and technician can start to visualize the planned outcome, with everything being easily reversible or alterable.

Each posterior mock-up was delivered, stamping a flowable composite (Tetric EvoFlow Bulk Fill, Ivoclar Vivadent) or a temporary resin through the clear silicone index, sextant by sextant, leading to a connected temporary restoration that remains in place thanks to the undercuts below the contact points and eventually a spot-etching technique (Figs 9 to 11). The occlusion was checked and balanced.

For the index technique, in addition to a conventional prosthesis, it is crucial to perform a try-in of the final digital

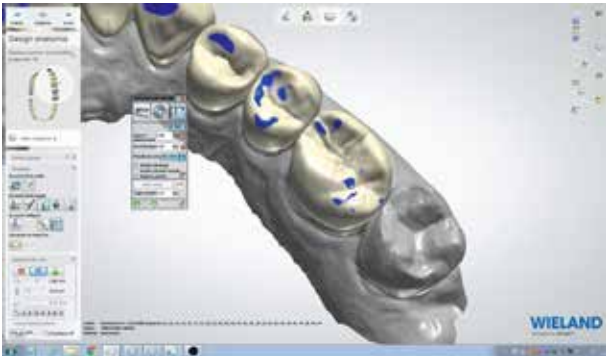


Fig 6 Occlusal points are checked and trimmed.

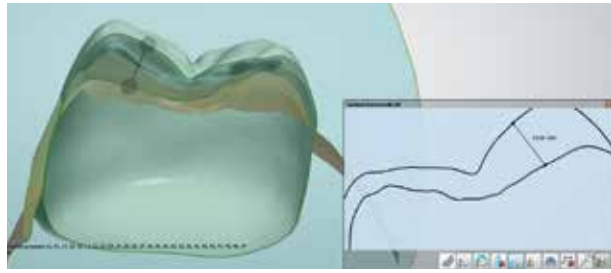


Fig 7 By clicking on the 2D option, it is possible to section each element and model, checking thicknesses, contact areas, and distance from antagonist of the entire digital wax-up.

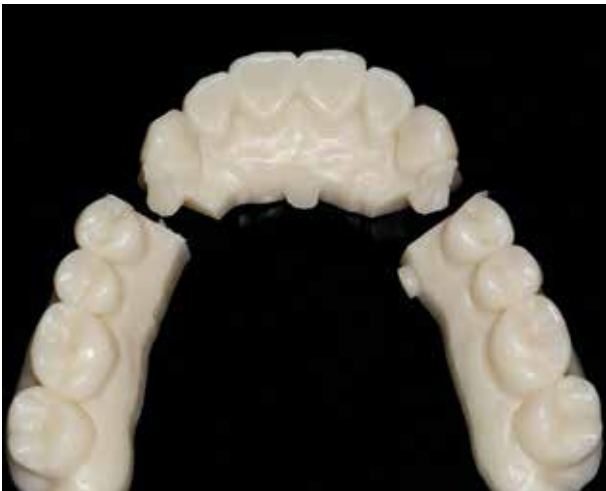

Fig 8 The PMMA-milled micromodels performed through CAM and created from the STL file.

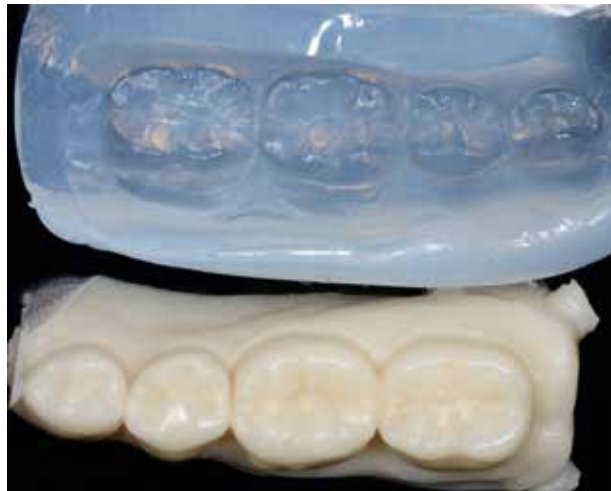

Fig 9 The transparent index is built on the PMMA-milled micromodel.

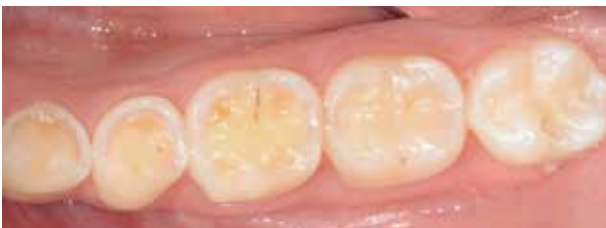

Fig 10 The initial situation showing moderate to severe dental wear due to erosion.

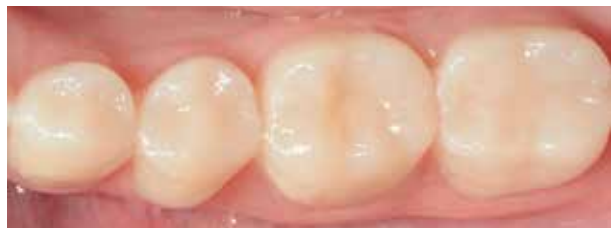

Fig 11 The temporary mock-up that will stay in place for a certain period, delivered by stamping (sextant by sextant) with a flowable composite or a temporary resin through the clear silicone index. The mock-up will stay in place thanks to the undercuts and a spot-etching technique.

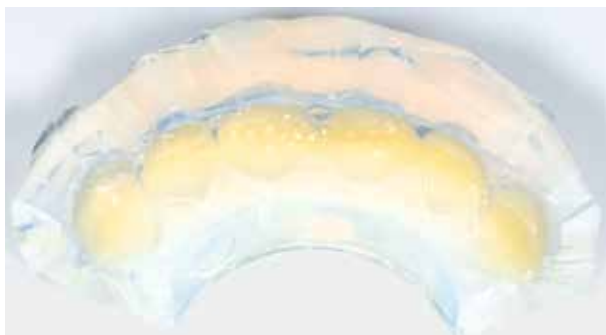


Fig 12 The transparent silicone key filled with a flowable composite or temporary resin material ready to be molded on sextant 2. Note that just for the temporary phase the indices are not cut into single keys.

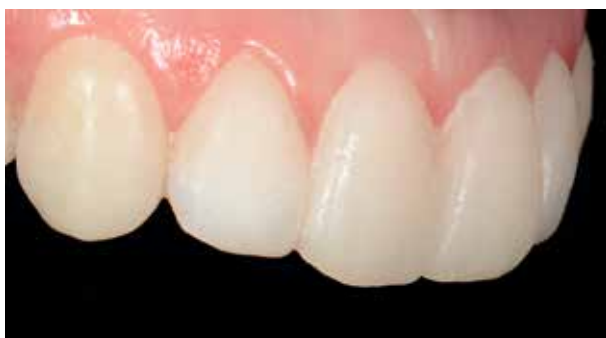

Fig 13 The temporary mock-up made of flowable composite or temporary resin through the clear silicone index that will stay in place for a certain period thanks to the undercuts and a spot-etching technique. After some time, after checking phonetic function and the esthetics of the new VDO, the temporary restoration can be removed, and the molding process can take place through the single indices.

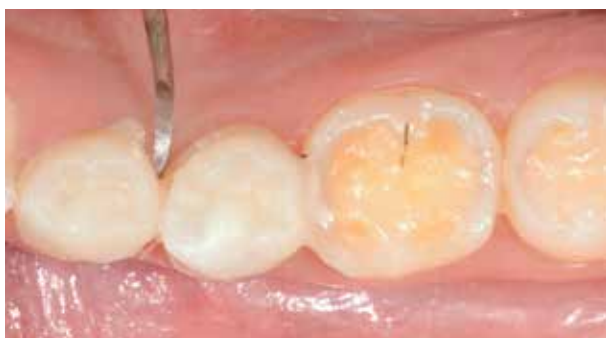

Fig 14 After a period of time, once the phonetic function and esthetics of the new VDO have been checked, the temporary restoration on the six sextants is removed with a scaler.

wax-up with an anterior mock-up to evaluate phonetics and esthetics and to give the clinician, technician, and patient a better understanding of the preview. A direct composite mock-up from tooth 15 to 25 was made from a transparent silicone key fabricated on the digital restorative wax-up models performed with a molding machine or 3D printer (Figs 8, 12, and 13).

A few weeks later, once esthetics, phonetics, and static and dynamic occlusion had been evaluated (as well as the muscles and the TMJ after the raising of the OVD), the provisional restorations on the six sextants were removed with a scaler (Fig 14).

Following the mock-up evaluations, the correct alterations of shape and length, if needed, can be carried out on the digital restorative wax-up files prior to the final index construction.

The keys of each sextant were cut with a surgical blade to achieve six single transparent indices on sextants 2 and 5 (from canine to canine), and four on sextants 1, 3, 4, and 6 (two premolars and two molars for each sextant).

The index technique can begin on the anterior or posterior sextants, depending on the diagnostic findings phase. To avoid any problems, the correct series of appointments should be scheduled at the start of treatment so that the entire therapy can be carried out in the shortest possible time to avoid leaving the patient in an uncomfortable occlusal situation.

Posterior index technique restorations

The index was created by injecting the material over the digital restorative

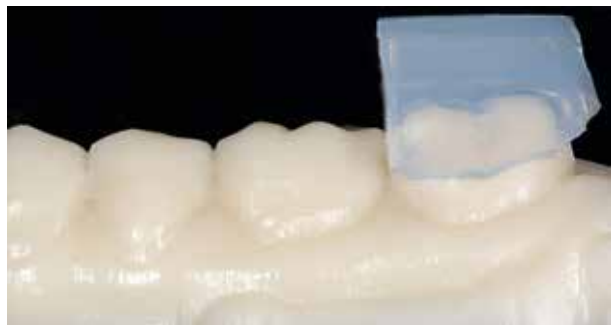

Fig 15 The clear index created on the PMMA digital wax-up sectional model. It can be removed from the model after curing.



Fig 16 The full index is cut with a surgical blade in the interproximal area to achieve four single indices.

Fig 17 For each single index there is a try-in on the cast to check the landmarks at the buccolingual equatorial regions. The fitting and the interproximal adaptation around the marginal ridge are also checked.



wax-up sectional cast, previously carried out when planning the full rehabilitation through an esthetic and functional analysis. When curing was completed (3 min, with Shore A hardness 72) (Fig 15), the index was removed from the cast and trimmed with a surgical blade. Care was taken to separate the single elements to achieve a single index for each tooth requiring restoration (Fig 16). Each single index was tried on the cast to check the fit around each digital restorative waxing (Fig 17).

The teeth involved in the rehabilitation were isolated with rubber dam (Fig 18), and each transparent index was tried in the mouth and eventually modified with a surgical blade to achieve a very precise fit to the landmarks. Checking the landmarks is very important for the correct positioning of each single index in order

to perform and achieve a predictable copy-and-paste restoration. For teeth that only have to be lengthened (usually the posterior sextants, and sextant 5), the landmarks for the index are located at the tooth equator on the buccal and linguopalatal aspects (Fig 19). The fit of

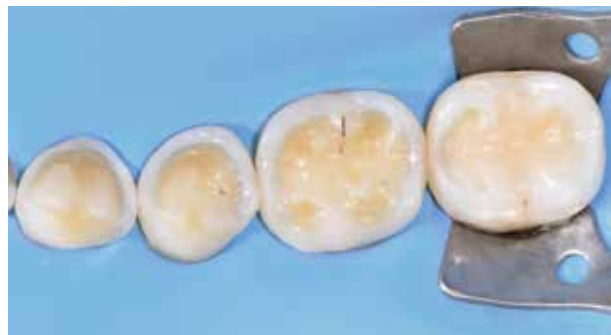

Fig 18 After rubber dam isolation, the index fit is checked before and after the sectional matrices, and wedges are placed.

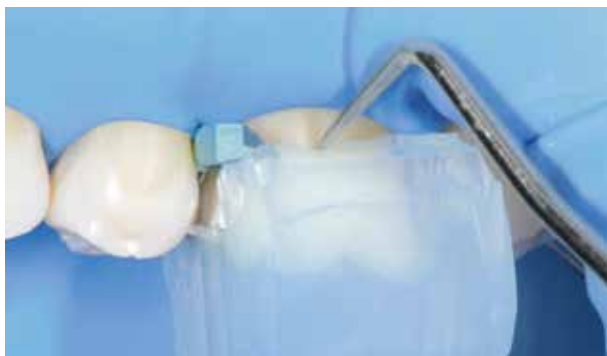

Fig 19 On the posterior sextants, the index landmarks are located at the tooth equatorial on the buccolingual aspect. Note that the mesiodistal sectional matrices are within the key in order to have better composite control during the molding process.

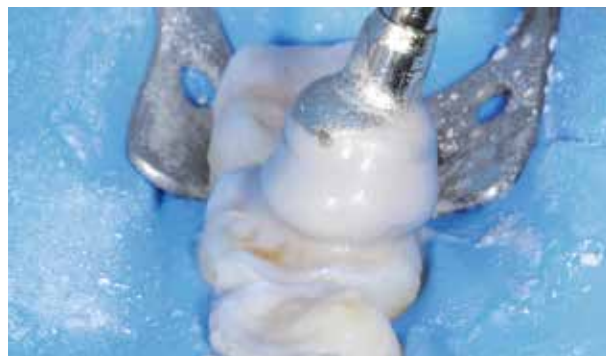

Fig 20 Being a no-prep technique, the enamel and dentin are cleansed before the adhesive procedures with pumice and chlorhexidine to remove the biofilm.

each index was also checked by placing two matrices interproximally to achieve a proper tooth separation, a proper proximal shape, and less excess material flow during the molding process. If required, the indices are again trimmed until a proper fit is achieved (Fig 19).

The teeth were not prepared with rotary instruments but were cleansed with pumice and chlorhexidine on the enamel and dentin (Fig 20).

Furthermore, as a pretreatment, sandblasting was carried out with alumina oxide 50 μ for 5 s on the aprismatic enamel or no-prepped enamel (Fig 21), while on the eroded dentin a slight bur preparation was carried out to achieve better adhesion³¹ (Fig 22). A three-step etch-and-rinse technique was performed^{32,33} on one tooth at a time, followed by light curing for 60 s.

The preheated composite was applied on the tooth with a spatula (the enamel on the perimeter and the dentin on the central occlusal part). Then, the two matrices that were placed to protect the adjacent teeth were bent toward the

tooth center after the heated composite resin was placed on the occlusal surface (and partially on the linguopalatal and buccal surfaces) with a spatula. This was done to achieve a better proximal composite shape while molding, and to have less composite excess during the finishing steps. The single transparent index, previously tried and modified accordingly, was fitted on the top prior to polymerization, ensuring that the matrices were within the index. Keeping two fingers on the key and using a probe, the clinician removed the excess composite that flowed out at the equatorial region. Thereafter, light curing was performed for 60 s through the key, and for another 120 s after the removal of the key.

Finishing was performed with interproximal metal strips, paper discs, fine diamond burs, and an Eva handpiece (Fig 23). Once the clinician had completed the index technique direct restoration, the same steps could be carried out on the adjacent teeth to finalize the planned rehabilitation of that sextant. After checking the occlusion, polishing

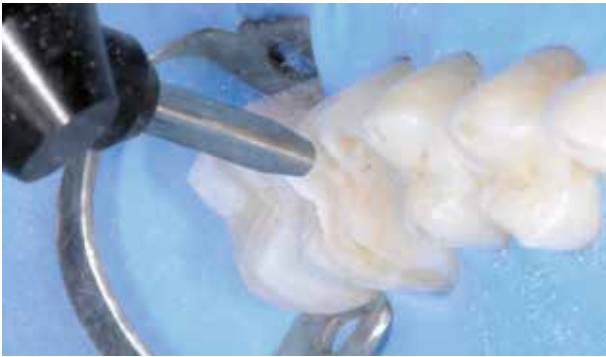


Fig 21 As a pretreatment, the aprismatic or no-prepped enamel is sandblasted with alumina oxide 50 μ for 5 s. This step leads to better adhesion.

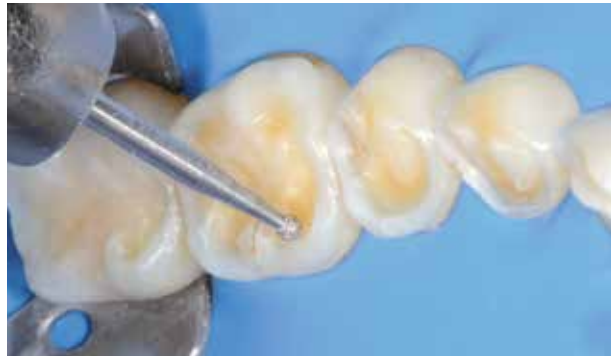

Fig 22 On eroded dentin, a slight bur preparation is carried out to achieve better adhesion.

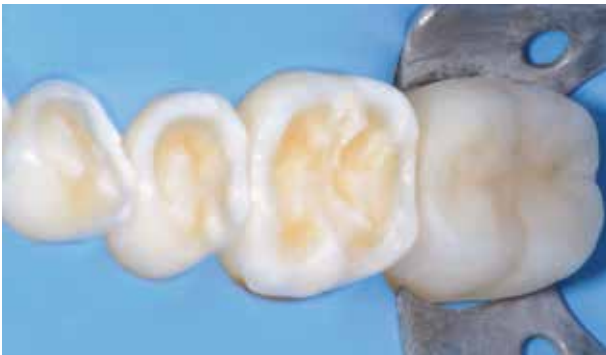

Fig 23 The second molar has been restored with the index technique protocol. One by one, all the other teeth of this sextant will be restored in the same session.

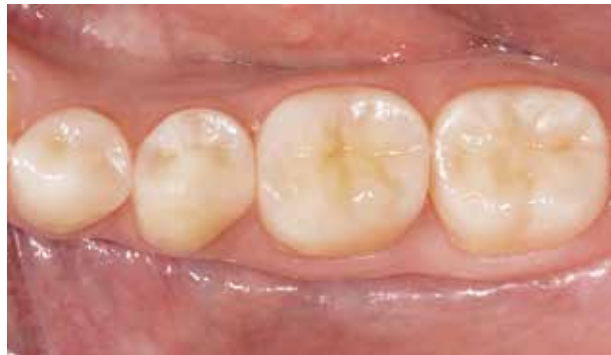

Fig 24 Occlusal view of the sextant restored with the index technique protocol at a follow-up.

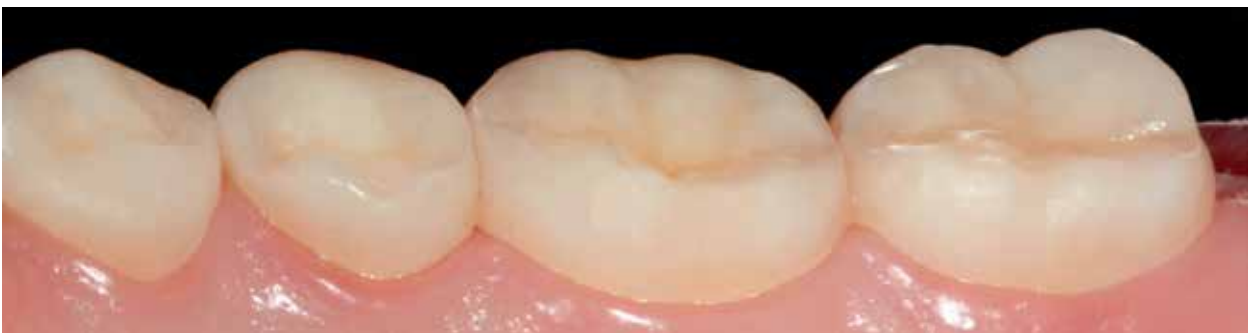

Fig 25 Lingual view of the sextant restored with the index technique protocol at a follow-up.

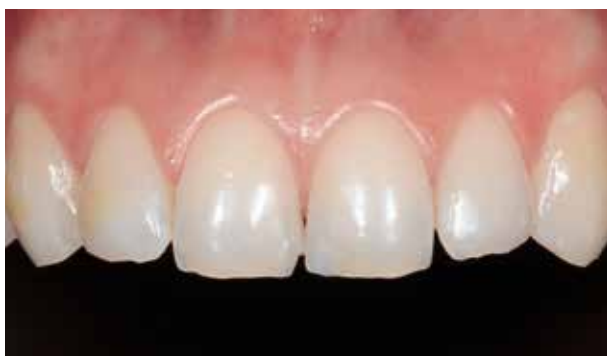

Fig 26 Initial situation at sextant 2.

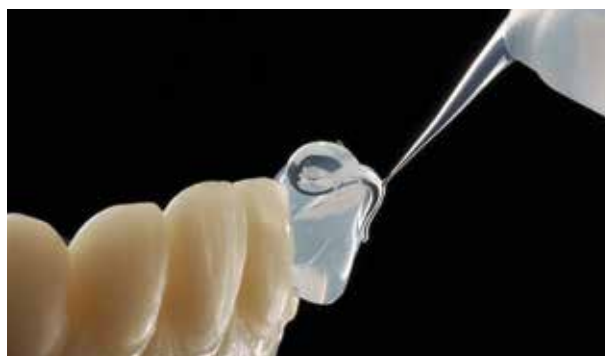

Fig 27 The clear silicone extruded on the PMMA digital wax-up sectional model.

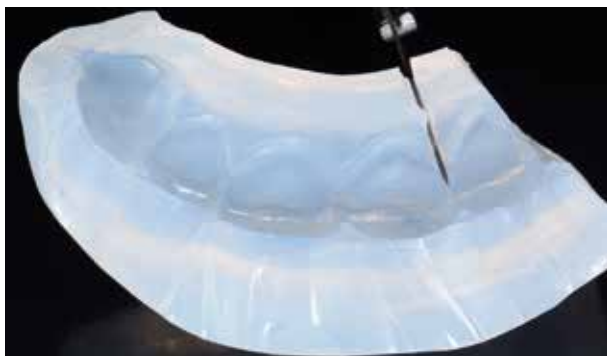


Fig 28 For the final molding process, the sextant 2 index is cut with a surgical blade, which is accurate in the proximal area, in order to achieve 6 single keys.

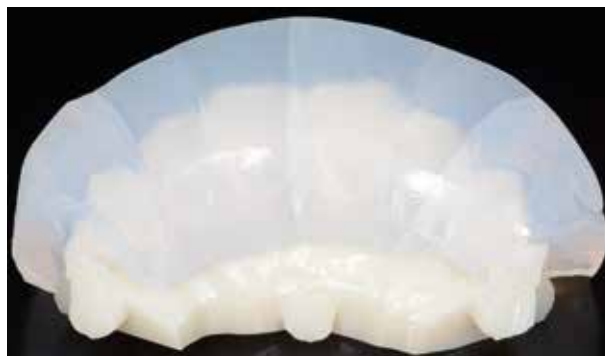

Fig 29 The six single indices placed on the sextant 2 PMMA digital wax-up sectional model.

was carried out with rubber burs and aluminum oxide paste (Figs 24 and 25).³⁴

Usually, in the same appointment, the antagonist sextant is also restored using the same protocol.

It is possible at this stage, before dismissing the patient, to provisionally restore the posterior sextants that have not been restored with the index technique protocol. This is done with a loaded flowable or acrylic resin material without performing an adhesive protocol, or by spot etching on the buccal and lingual-palatal surfaces through the transparent indices built on the posterior sextants of the digital wax-up, taking advantage of

the undercuts below the contact areas for retention (see Figs 9 and 11). As an alternative, only the first molars, which have not yet been restored with the index technique protocol, can be temporarily restored with the indices. This would allow for improved posterior occlusal stability in the interim period between appointments.

Anterior index technique restorations

According to the article on the index technique published in this journal in 2015,⁹ there are three options to manage



sextant 2: incisal edge (IE); palatal/incisal (PI); and full veneering (FV). The option selected for this case was FV, which allows for the restoration of teeth that have lost volume three-dimensionally on the incisal, buccal, and palatal aspects (Fig 26).

A transparent silicone key (Memosil 2 or Temp Silk) of the final wax-up was made on sextant 2 (Fig 27). Following chemical curing at 2 bar pressure for 20 min, the key was cut with a surgical blade to achieve six single transparent indices (Figs 28 and 29). Each index was tried on the cast to check for the correct proximal and marginal fit (Fig 30). Where it is more convenient (usually only on sextant 2), a small hole can be made with a bur on each transparent index, on the buccal and palatal middle-third area, to allow for better flow of the excess composite during the molding process (Fig 31).

Rubber dam was then placed to treat sextant 2 (Fig 32), and each single

index was tried in the mouth to check for proper fit, and eventually trimmed with a surgical blade. For esthetic reasons only, a bevel can be performed on the buccoincisal edge to achieve better chromatic integration (in this case, no bevel was carried out). The teeth were not prepared with rotary instruments, but cleansing with pumice and chlorhexidine on the enamel and dentin was carried out (Fig 33). Furthermore, as a pretreatment, sandblasting was performed with alumina oxide 50 μ for 5 s on the aprismatic (or no-prepped) enamel, whereas on the eroded dentin a slight bur preparation was carried out to achieve better adhesion.³¹

Two sectional matrices (3D Fusion, Garrison Dental) and wedges were placed interproximally in order to set up a correct shape for the molding process, to protect the adjacent teeth, and to have less excess material to remove during the finishing steps. Where required, the key was again trimmed until a proper

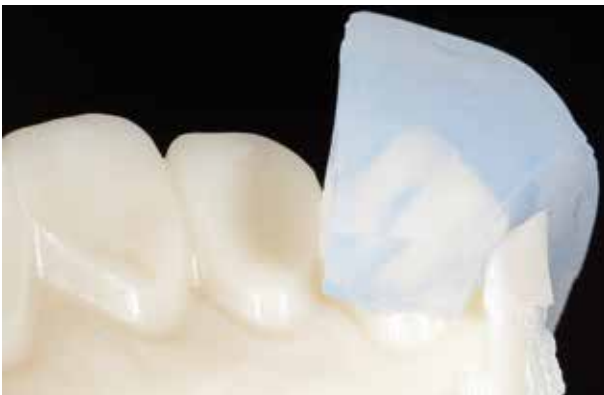

Fig 30 Checking the proximal fit of the single index. While on the marginal area (palatal and buccal) – since the digital wax-up is performed 1.5 to 2 mm away from the sulcus – the index is also cut coronally to achieve a good fit without interference with the rubber dam during the molding process.



Fig 31 Two small holes (only on the sextant 2 single indices) can be made with a bur on the buccal and palatal middle-third to allow for a better flow of excess composite during the molding process.

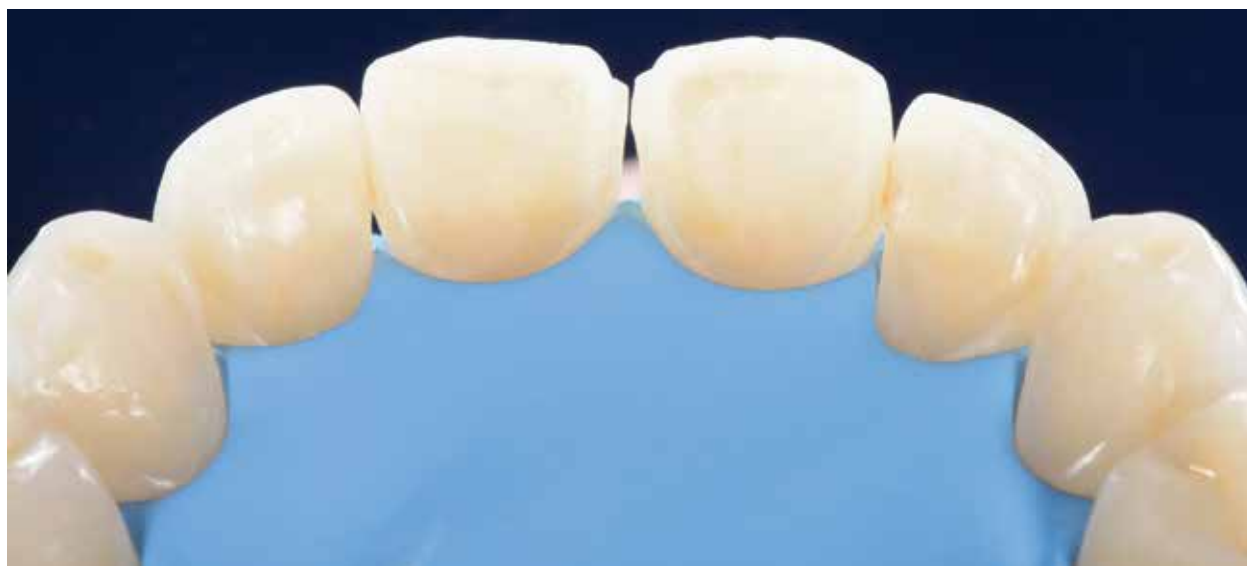

Fig 32 Rubber dam is placed on sextant 2.

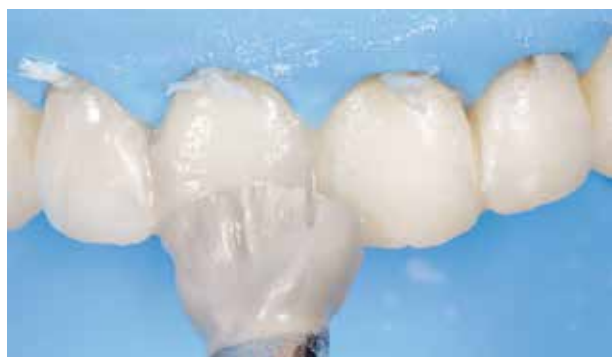

Fig 33 Since this is a no-prep technique, cleansing with pumice and chlorhexidine on enamel and dentin is carried out before the adhesive steps only to remove the biofilm. For esthetic reasons only, a bevel on the buccoincisor edge can be performed. In this case, no bevel was carried out.

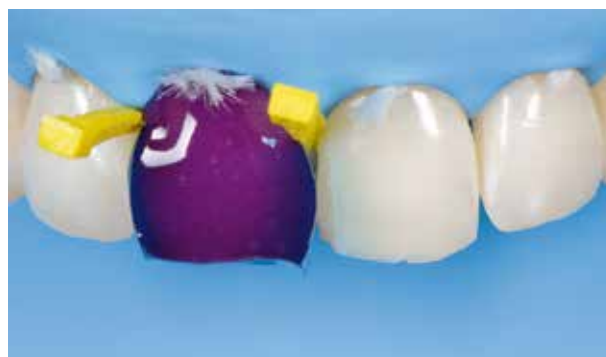

Fig 34 After sandblasting, a no-prep etching of the tooth tissue is carried out.

fit was achieved, also with the matrices in place. A three-step etch-and-rinse technique was performed^{32,33} (Figs 34 and 35) on one tooth at a time, followed by light curing for 60 s on the buccal and palatal surfaces, or simultaneously with two devices on both surfaces (Fig 36). Composite shades were chosen prior to rubber dam placement, and then heated

prior to placing the increments on each tooth. The two matrices that were placed to protect the adjacent teeth were bent toward the tooth center. The preheated composite resin was then layered with a spatula (dentin cervical-third to middle-third, and enamel middle-third to incisal-third) on both the buccal and palatal surfaces (Fig 37), to achieve a better

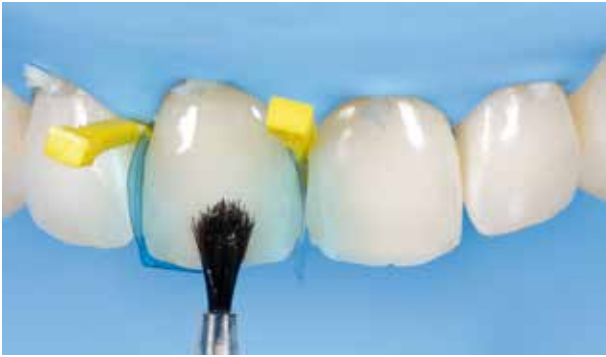

Fig 35 A bonding agent is placed on the no-prep buccal and palatal surfaces.

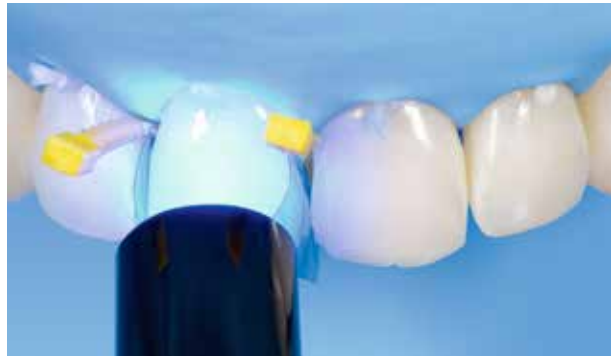

Fig 36 Light curing for 60 s on each surface with one device or 60 s with two devices simultaneously on both surfaces.

proximal composite shape while molding as well as less composite excess during the finishing steps. A layering option on sextant 2, in a molding approach, can also be performed with the 'index cut back technique.'³⁵

The index was then placed on the first tooth. This is usually done starting from tooth 11 or 21. Extra care should be taken when placing the transparent silicone indices, since the only true landmarks for checking for correct fit are both palatally and buccally at the emergence level near the gingival margin where the rubber dam ligatures are placed (Fig 38), since in this case all of the clinical crown required restoring. A similar amount of enamel and dentin composite was pressed off at the cervical proximal areas and through the holes, performed with a bur during the molding process. Finger pressure was maintained buccally and palatally while the excess composite was removed with a probe or spatula. The site was then

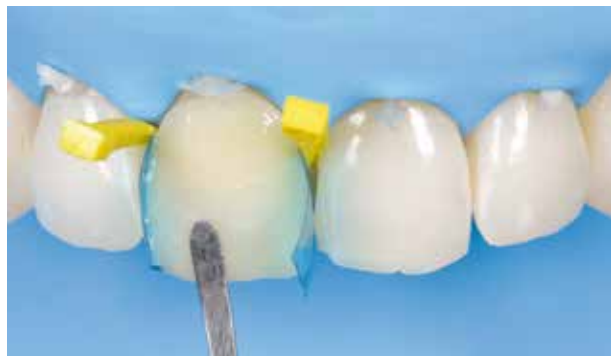

Fig 37 After placing the matrices and wedges, the preheated composite is layered (dentin on cervical-third to middle-third, and enamel on middle-third to incisal-third) on both the buccal and palatal surfaces.

light cured, according to the previous article published in this journal in 2015,⁹ with two devices through the silicone index, initially for 60 s (Fig 39), and then for a further 120 s on both surfaces following index removal. Finishing of the composite excess was performed with interproximal metal strips, paper discs, fine diamond burs, and an Eva handpiece.

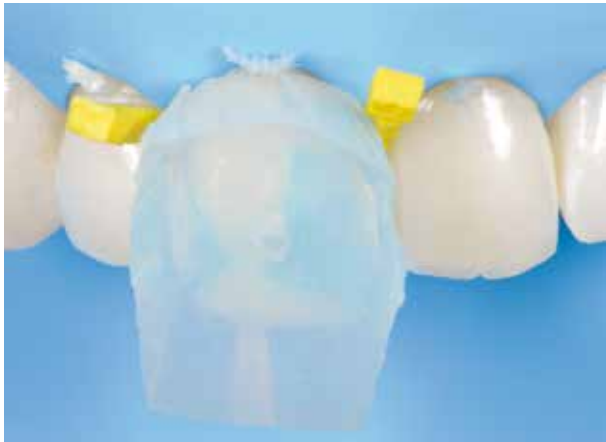

Fig 38 The single key that was tried before and eventually modified with the surgical blade is placed on the tooth. The index landmarks are located buccopalatally at the cervical region where the rubber dam ligatures are placed, and the matrices are within the key.

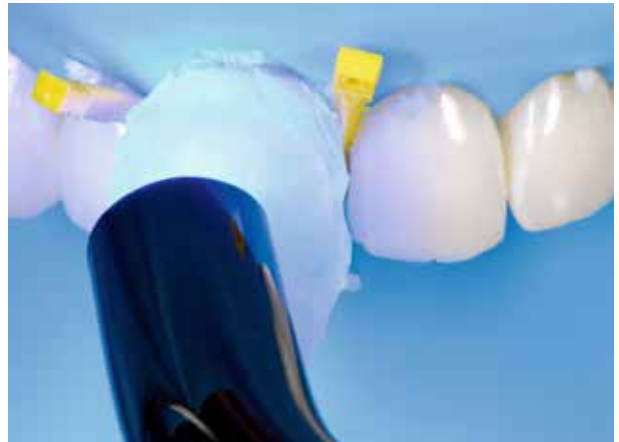

Fig 39 Once the excess composite has been removed at the cervical margins with a probe, light curing takes place for 60 s on each surface through the index or for 60 s with two devices placed on the buccal and palatal surfaces.

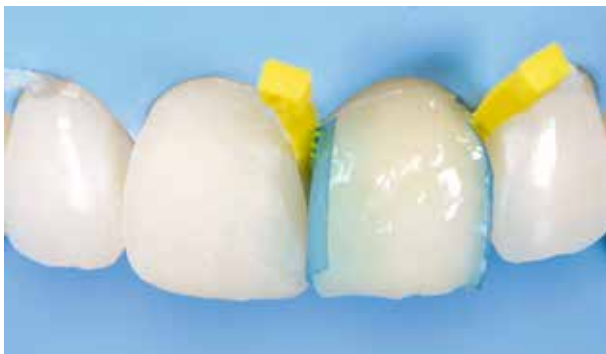

Fig 40 After the finishing steps on tooth 11 are carried out with paper discs, metal strips, diamond burs, and an Eva handpiece, the molding process can take place on the adjacent tooth using preheated composite, with the same protocol described previously.

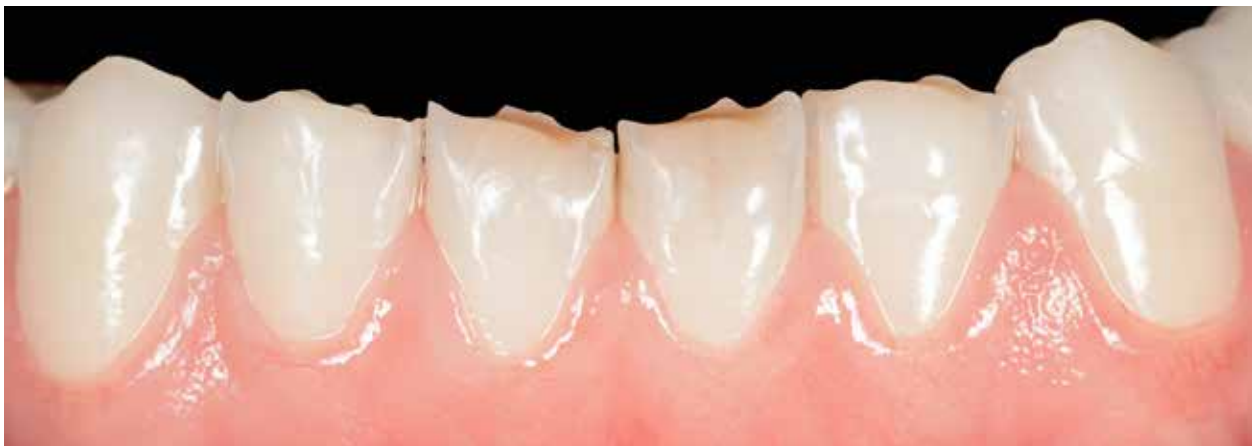

Fig 41 Initial situation on sextant 5.

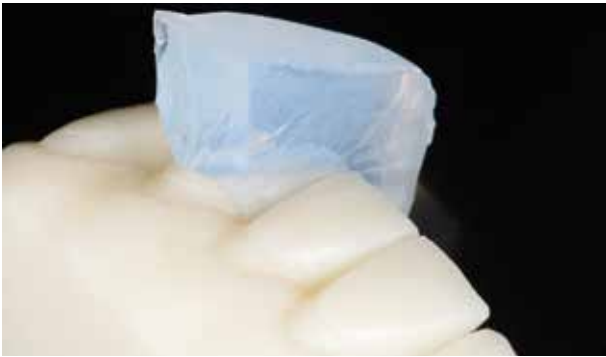

Fig 42 Checking the correct fit at the proximal area and the buccolingual equatorial landmarks as the posterior sextants.

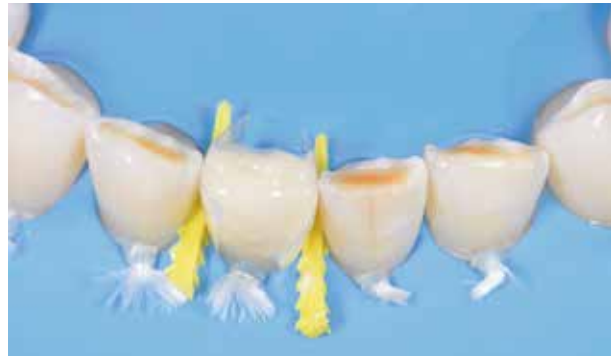

Fig 43 The preheated composite (dentin and enamel) is placed after the wedges, matrices, and adherence protocol.

This protocol was then carried out for all the other teeth of sextant 2 (Fig 40).

This protocol was also performed on sextant 5 (Fig 41) in the same appointment, the only difference being that only the incisal edges and the buccal surfaces up to the equatorial region required lengthening and volume increase with the index technique, based on the previously developed digital wax-up (Figs 42 to 45). The ultimate goal at the end of this appointment was to have a simultaneous bilateral contact on the canines,³⁶ and only a shimming contact

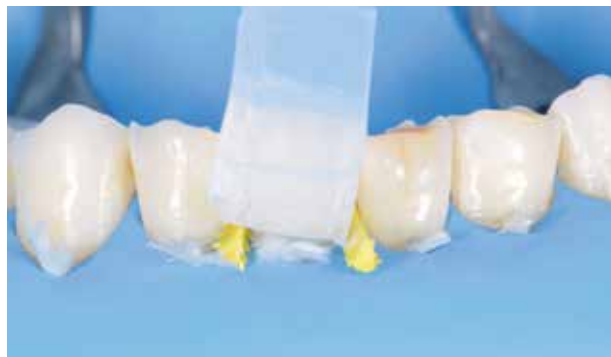

Fig 44 The index that was previously tried is then placed, and the index technique can be carried out through a copy-and-paste approach.

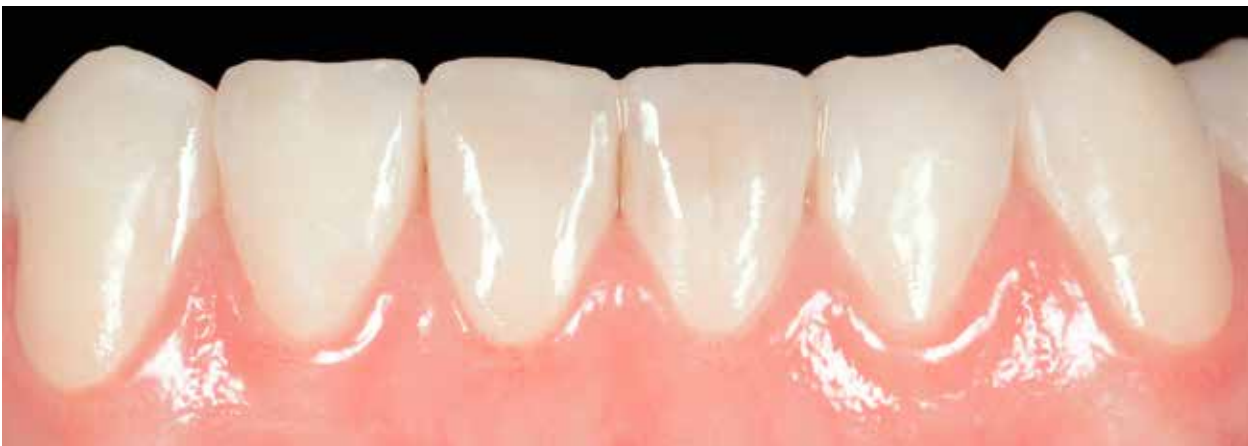

Fig 45 The final situation at a follow-up, after the six index technique restorations have been performed.

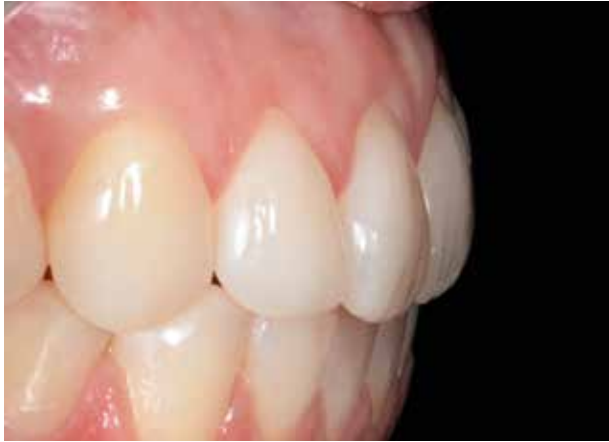

Fig 46 Lateral view of the anterior sextants restored with the index technique protocol. On sextant 2, it is possible to see the finishing line of the restorations at the cervical region, which is approximately 2 mm coronal from the soft tissue.

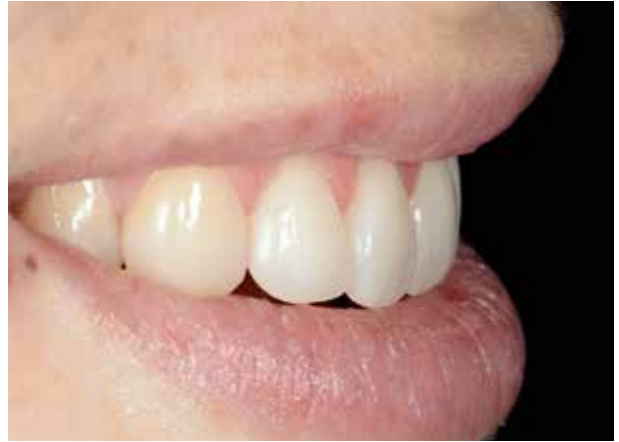

Fig 47 Lateral view of sextant 2, checking phonetics and esthetics within the inferior lip context.

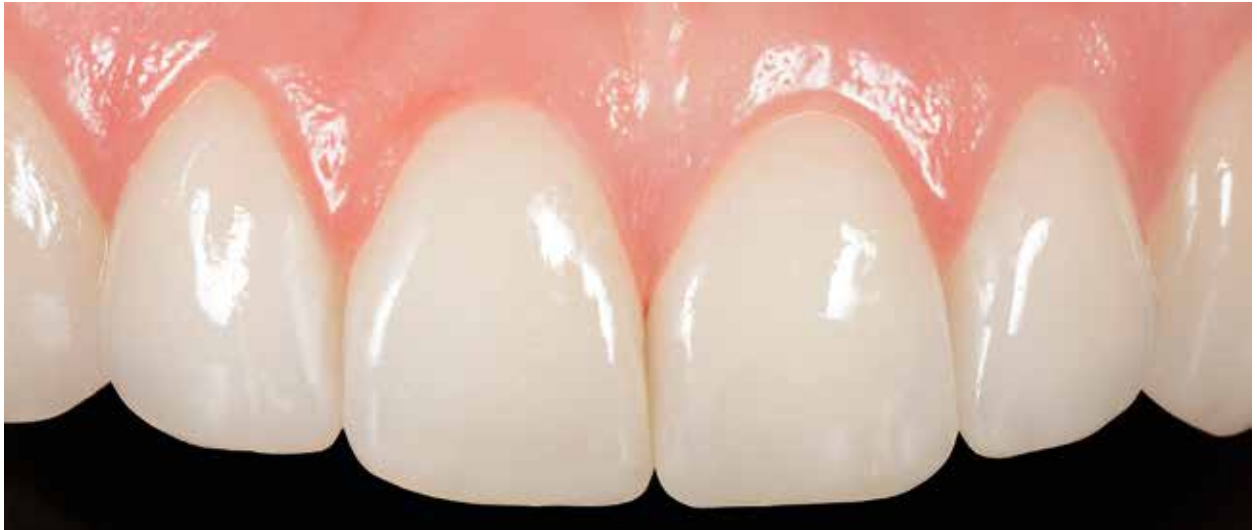

Fig 48 Final situation, frontal view.

on the incisors that could be checked with 8 μ m shim stock (Hanel ShimStock, Coltene) and 12 μ m articulating paper (Hanel Occlusion Foil, Coltene).

Complications and repair

One of the significant benefits of using composite resin for a full-mouth rehabilitation with the index technique is that the most likely complications are wear and chipping, while full loss or detachment



of the restoration is an unlikely occurrence. Partial failure can easily be repaired with fresh composite following proper surface treatment: sandblasting, silanization, and the bonding of all surfaces.²

Nanohybrid composite has good wear characteristics,³⁷ and a superficial gloss is maintained in the long term following polishing (Figs 46 to 53). Further, it is very easy to repolish this material during patient recall visits.

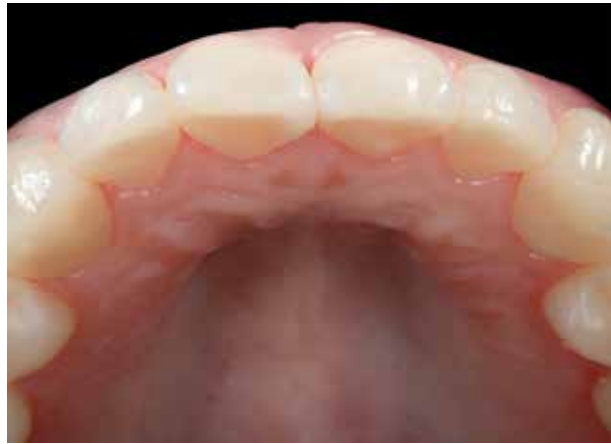

Fig 49 Final situation, occlusal view.

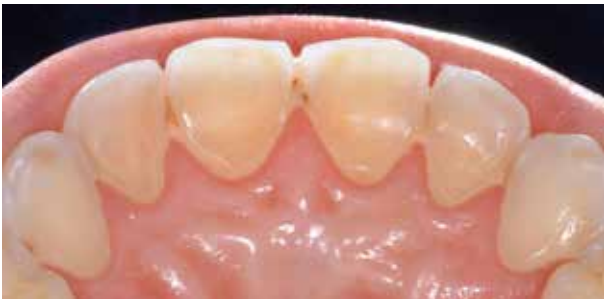

Fig 50 Initial situation, palatal view.

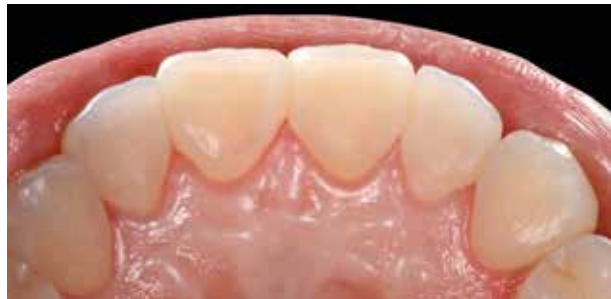

Fig 51 Final situation, palatal view.

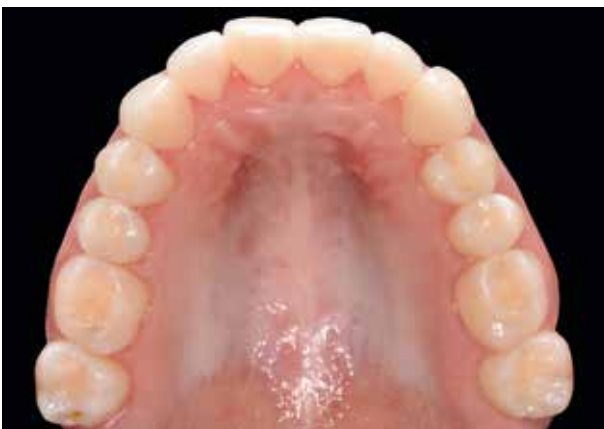

Fig 52 Final situation, maxillary arch.

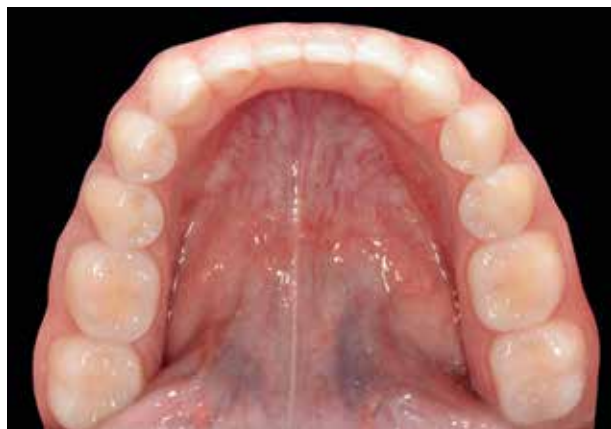

Fig 53 Final situation, mandibular arch.



Conclusions

The digital index technique protocol proposes a conservative and alternative approach for the treatment of moderate and severe tooth wear, based mainly on minimally or non-invasive copy-and-paste composite restorations on both anterior and posterior teeth.

Ideally, dentistry should be additive whenever possible, not subtractive-additive. Increasing the OVD leads to less tooth structure removal and improved biomechanics.³⁸ Adhesion and composite resin have become very reliable,³⁹ allowing restorations to be retained without the need for retentive cavity preparations. Furthermore, especially on the anterior sextants where undercuts show up a direct molding technique, this protocol allows the clinician to be extremely conservative. With indirect restorations, however, a preparation should be performed.

Total reversibility is another important characteristic of this technique. It allows the clinician to restore the patient's initial situation at the end of treatment (if, for

any reason, this becomes necessary), although it should be borne in mind that composite removal after adhesive protocols is not easy to perform due to bonding strength and composite chromatic integration with the natural tooth.

Another positive characteristic of this technique is the relative ease with which chipping or restorative failure can be managed by applying a simple adhesive protocol. This makes the overall treatment fairly simple. A further benefit over traditional prosthetic rehabilitations is that this technique requires shorter clinical time to finalize a case, which in turn influences management costs. The only real expense for the clinician is the digital or analog restorative wax-up carried out by the technician for the purposes of correct treatment planning and to obtain the required transparent index.

Finally, the driving force behind this approach is to intercept tissue destruction and avoid or postpone a more biologically invasive and financially costly prosthetic solution.¹ Long-term studies are needed to further understand the potential of this technique.

References

1. Loomans B, Opdam N, Attin T, et al. Severe Tooth Wear: European Consensus Statement on Management Guidelines. *J Adhes Dent* 2017;19: 111–119.
2. Dietschi D, Argente A. A comprehensive and conservative approach for the restoration of abrasion and erosion. Part 1: concepts and clinical rationale for early intervention using adhesive techniques. *Eur J Esthet Dent* 2011;6:20–33.
3. Selwitz RH, Ismail AI, Pitts NB. Dental caries. *Lancet* 2007;369:51–59.
4. Park BK, Tokiwa O, Takezawa Y, Takahashi Y, Sasaguri K, Sato S. Relationship of tooth grinding pattern during sleep bruxism and temporomandibular joint status. *Cranio* 2008;26:8–15.
5. Spear F, Kinzer G. Approaches to Vertical Dimension. In: Cohen M (ed). *Interdisciplinary Treatment Planning: Principles, Design, Implementation*. Chicago: Quintessence, 2008: 249–281.
6. Fradeani M, Barducci G, Bacherini I, Brennan M. Esthetic rehabilitation of a severely worn dentition with minimally invasive prosthetic procedures (MIPP). *Int J Periodontics Restorative Dent* 2012;32:135–147.
7. Carroll WJ, Woelfel JB, Huffman RW. Simple application of an anterior jig or leaf gauge in routine clinical practice. *J Prosthet Dent* 1988;59:611–617.
8. Shankland WE 2nd, Ralston SJ. The fabrication and use of a leaf gauge to locate centric relation. *Ohio Dent J* 1983;57:43–45.



9. Ammannato R, Ferraris F, Marchesi G. The "index technique" in worn dentition: a new and conservative approach. *Int J Esthet Dent* 2015;10:68–99.
10. Ibsen RL, Ouellet DF. Restoring the worn dentition. *J Esthet Dent* 1992;4:96–101.
11. Christensen GJ. A new technique for restoration of worn anterior teeth. *J Am Dent Assoc* 1995;126:1543–1546.
12. Darbar UR, Hemmings KW. Treatment of localized anterior toothwear with composite restorations at an increased occlusal vertical dimension. *Dent Update* 1997;24:72–75.
13. Marais JT. Restoring palatal tooth loss with composite resin, aided by increased vertical height. *SADJ* 1998;53:111–119.
14. Lussi A, Jaeggi T, Schaffner M. Prevention and minimally invasive treatment of erosions. *Oral Health Prev Dent* 2004;1(2 suppl):321–325.
15. Sundaram G, Bartlett D, Watson T. Bonding to and protecting worn palatal surfaces of teeth with dentine bonding agents. *J Oral Rehabil* 2004;31:505–509.
16. Hastings JH. Conservative restoration of function and aesthetics in a bulimic patient: a case report. *Pract Periodontics Aesthet Dent* 1996;8:729–736.
17. Hemmings KW, Darbar UR, Vaughan S. Tooth wear treated with direct composite restorations at an increased vertical dimension: results at 30 months. *J Prosthet Dent* 2000;83:287–293.
18. Bartlett D, Sundaram G. An up to 3-year randomized clinical study comparing indirect and direct resin composites used to restore worn posterior teeth. *Int J Prosthodont* 2006;19:613–617.
19. Redman CD, Hemmings KW, Good JA. The survival and clinical performance of resin-based composite restorations used to treat localised anterior tooth wear. *Brit Dent J* 2003;194:566–572.
20. Poyser NJ, Briggs PF, Chana HS, Kelleher MG, Porter RW, Patel MM. The evaluation of direct composite restorations for the worn mandibular anterior dentition – clinical performance and patient satisfaction. *J Oral Rehabil* 2007;34:361–376.
21. Smales RJ, Berekally TL. Long-term survival of direct and indirect restorations placed for the treatment of advanced tooth wear. *Eur J Prosthodont Restor Dent* 2007;15:2–6.
22. Vailati F, Belser UC. Full-mouth adhesive rehabilitation of a severely eroded dentition: the three-step technique. Part 1. *Eur J Esthet Dent* 2008;3:30–44.
23. Vailati F, Belser UC. Full-mouth adhesive rehabilitation of a severely eroded dentition: the three-step technique. Part 2. *Eur J Esthet Dent* 2008;3:128–146.
24. Vailati F, Belser UC. Full-mouth adhesive rehabilitation of a severely eroded dentition: the three-step technique. Part 3. *Eur J Esthet Dent* 2008;3:236–257.
25. Spreafico RC. Composite resin rehabilitation of eroded dentition in a bulimic patient: a case report. *Eur J Esthet Dent* 2010;5:28–48.
26. Attin T, Filli T, Imfeld C, Schmidlin PR. Composite vertical bite reconstructions in eroded dentitions after 5.5 years: a case series. *J Oral Rehabil* 2012;39:73–79.
27. Mesko ME, Sarkis-Onofre R, Cenci MS, Opdam NJ, Loormans B, Pereira-Cenci T. Rehabilitation of severely worn teeth: A systematic review. *J Dent* 2016;48:9–15.
28. Olivera AB, Marques MM. Esthetic restorative materials and opposing enamel wear. *Oper Dent* 2008;33:332–337.
29. Vailati F, Carciofo S. Treatment planning of adhesive additive rehabilitations: the progressive wax-up of the three-step technique. *Int J Esthet Dent* 2016;11:356–377.
30. Versluis A, Tantbirojn D, Douglas WH. Do dental composites always shrink toward the light? *J Dent Res* 1998;77:1435–1445.
31. Zimmerli B, De Munck J, Lussi A, Lambrechts P, Van Meerbeek B. Long-term bonding to eroded dentin requires superficial bur preparation. *Clin Oral Invest* 2012;16:1451–1461.
32. Breschi L, Mazzoni A, Ruggeri A, Cadenaro M, Di Lenarda R, De Stefano Dorigo E. Dental adhesion review: aging and stability of the bonded interface. *Dent Mater* 2008;24:90–101.
33. Gondo R, Lopes GC, Monteiro JRS, et al. Microtensile bond strength of resin to enamel: effect of enamel surface preparation and acid etching time. *J Dent Res* 2003;82:190 (Abstract 1424).
34. Ferraris F. Adhesion, layering, and finishing of resin composite restorations for class II preparations. *Eur J Esthet Dent* 2007;2:210–221.
35. Ammannato R, Ferraris F, Allegri M. The "index cut back technique": a three-dimensional guided layering approach in direct class IV composite restorations. *Int J Esthet Dent* 2017;12:450–466.
36. Alonso A, Albertini J, Bechelli A, Braverman L. *Guia pratica del tratado de oclusion y prostodontica integral*. Ed Clinica de Rehabilitacion Oral y Occlusion, 1988.
37. Ilie N, Rencz A, Hickel R. Investigations towards nano-hybrid resin-based composites. *Clin Oral Invest* 2013;17:185–193.
38. Torbjörner A, Fransson B. Biomechanical aspects of prosthetic treatment of structurally compromised teeth. *Int J Prosthodont* 2004;17:135–141.
39. Van Meerbeek B, De Munck J, Yoshida Y, et al. Buonocore memorial lecture. Adhesion to enamel and dentin: current status and future challenges. *Oper Dent* 2003;28:215–235.